

OBJECTIVE: To determine the significance of facet joint arthropathy (FJA) and the role of discopathy in chronic mechanical lower back pain (CMLBP).

METHODS: This is a retrospective study of 732 patients with CMLBP who were treated between 1997 and 2007. All patients had received injections of methylprednisolone and bupivacaine into the facet joints of L3-4, L4-5, and L5-S1. None had tumor, infection, or major trauma causing fracture of the spine, disruption of the major ligaments of the lumbosacral spine, or cauda equina syndrome. Patients were evaluated in the recovery room before discharge, 1 week after the procedure, and until the pain recurred. Charts were reviewed to evaluate the efficacy of facet joint injection (FJI) and the relevance of the CMLBP to FJA. Magnetic resonance imaging findings were reviewed for each patient to determine the role of discopathy in the outcomes of the patients who had had FJI.

RESULTS: The overall success rate was 73.2%, with a mean duration of efficacy of 77.9 days. In patients with PSE factors, the success rate was 67.9% with a mean duration of efficacy of 70.3 days. In those without PSE factors, the favorable initial response to FJI was 86.8%, with a mean duration of efficacy of 88.6 days.

CONCLUSION: This study suggests that FJA plays a major role in triggering CMLBP. Furthermore, this study questions the legitimacy of the Murphey and Marshall theories in the pathogenesis of LBP, a concept frequently cited in the literature as a frequent cause of CMLBP (40%).

Key Words: Low back pain, discopathy, facet joint arthropathy

INTRODUCTION

Given that the incidence of chronic mechanical lower back pain (CMLBP) due to benign disorders is high, it is important that the condition be diagnosed accurately and appropriate therapy applied [1]. CMLBP is only a description of a symptom complex. One of the most common causes of LBP is the frozen back syndrome, which may occur with or without surgery due to muscular contractures for immobilization of the injured lumbar spine to protect spinal cord and nerves, soft tissue structures, facet joints, and capsules and ligaments. Although numerous highly sophisticated diagnostic technologies are used, diagnosing the source of LBP can be difficult because the condition is often complicated by psychological, social, and economic factors. The assumption that the basic problem is degeneration of the lumbar discs is unproven. Acute LBP is often secondary to irritation or injury of musculoligamentous soft tissue structures innervated by the posterior primary ramus of the exiting spinal nerve, with pain being referred to the ipsilateral extremity. Many patients with acute LBP have a history of trauma and report LBP with diffuse, nonspecific hip, groin, and leg pain radiation. Although the leg pain often follows the proximal course of the sciatic nerve, unlike with true sciatica its termination and associated symptoms, such as appropriate sensory loss and paresthesias, are generally vague, histrionic, and nondermatomal. Moreover, objective neurological findings are typically absent [1].

The symptoms of CMLBP are usually worsened by activity and partially improved by rest. Physical activity, particularly bending, extending, twisting, and lifting, commonly aggravates the symptoms, whereas restriction of pain-producing activities results in improvement at least temporarily. Typical physical findings are nonspecific, including restricted range of motion of the spine, tight hamstring muscles, paravertebral muscle spasms, muscular trigger points, tenderness, and aggravation of symptoms on flexion or extension and straight leg raising tests.

Diagnosis of CMLBP is solely clinical; however, imaging studies may show degenerative spondylosis. Like asymptomatic individuals in whom imaging shows lumbar disc herniation and spinal stenosis, there are individuals with imaging abnormalities consistent with excessive motion

in dynamic flexion/extension who do not have clinical symptoms referable to those abnormalities. At present, the surgical treatment of CMLBP is arthrodesis of symptomatic vertebral motion segments in well-selected patients. However, a premature decision for surgical therapy inflicts additional soft tissue injury, aggravates the primary condition, and subjects the patient to unnecessary complications [1, 2].

MATERIALS and METHODS

A total of 732 patients with the diagnosis of CMLBP were treated by the senior author between 1997 and 2007 (Table 1). All patients had magnetic resonance imaging (MRI) of the lumbosacral spine. Each patient had facet joint injection (FJI) at L3-4, L4-5, and L5-S1 bilaterally. If imaging showed facet arthropathy at higher levels, those levels were also included. In patients who had undergone a spinal fusion procedure, the FJI was carried out at the levels above and below the fusion. There was no clinical presentation or screening test that could pinpoint the level of symptomatic facet joint arthropathy (FJA). However, if fusion at certain levels was contemplated, individual facet blocks could be done in different sessions. Such a multiple-session protocol was not practical or necessary for outpatient pain management. The subjective pain assessment was done and documented in each chart on the day of discharge and at 1 week, 4 weeks, and until the pain recurred, based on Odom's criteria. The second author (unfamiliar with the patients) reviewed the charts independently. For the treatment-failure group, psychological, social, and economic factors that could unfavorably affect outcomes were studied. Each chart was checked to make sure that our patient selection criteria and protocol had been followed with no deviation.

Inclusion Criteria:

1. The patient had had the diagnosis of MLBP (frozen back syndrome) for more than 3 months and did not respond to maximum medical treatment. (Three months has been proposed as a point of division between acute and chronic pain by the Subcommittee on Taxonomy of the International Association for the Study of Pain [3].)

2. The LBP was disabling to the degree that the patient could not perform his or her routine job without restrictions and his or her lifestyle had been affected.
3. The CMLBP was the chief complaint with or without leg pain.
4. MRI showed evidence of degenerative lumbar spondylosis.

Exclusion Criteria:

1. Patients with tumor, infection, and major trauma to the spine causing fracture or disruption of the major ligaments (supraspinous, interspinous, or longitudinal) were excluded from the treatment.
2. Patients with cauda equina syndrome who needed urgent surgery were excluded.

TECHNIQUE:

The patient is placed on the fluoroscopic-compatible operating table in prone position. Conscious sedation is used and the skin is prepared and draped in sterile fashion. Using the imaging intensifier, the facet joints bilaterally are identified from L3 to S1. The skin is marked with a marking pen. Skin wheals of 1% lidocaine are raised at the site of each facet joint block. Under fluoroscopic guidance, the 20-gauge 3.5-in needle is aimed towards the inferior aspect of each facet joint. After bony contact is made at each facet joint, the stylet is removed. Then 30 mL of preservative-free 0.25% bupivacaine and 160 mg of methylprednisolone are mixed. Then 5 mL of the mixture is injected very slowly into each facet joint. All of the needles are removed. The patient is then transferred to the recovery room.

RESULTS

We used Odom's criteria for subjective rating of pain relief. The overall success rate was 73.2% and pain relief lasted 0 to 5 years (mean of 77.9 days). The results were divided into four groups: excellent (182 patients); good (367 patients); fair (128 patients); and poor (55 patients). The first two groups were considered successful FJI and the last two groups were considered failed FJI (Table 2).

To analyze the reason for suboptimal subjective outcomes in the third and fourth groups (fair and poor outcomes), the second author reviewed patient charts and analyzed possible psychological, social, and economic factors for the outcomes. In the treatment-failure group, we identified and excluded patients with workmen's compensation or motor vehicle accident claims; patients who had a pending application for Social Security disability payments; patients with the diagnosis of reflex sympathetic dystrophy; patients dependent on narcotic pain killers; and patients with psychiatric problems (under the care of a psychiatrist or psychologist). Among the patients who had injection with fair and poor results (183 patients), 155 had psychological, social, or economic factors that may have accounted for the outcome. After elimination of these patients, the overall success rate increased to 86.8%, and the duration of treatment efficacy improved to 15 days to 5 years (mean of 88.6 days) (Table 3).

MRI findings read by our neuroradiologists showed that 686 patients had discopathy, a common condition in an asymptomatic population. MRI was positive for facet arthropathy in 457 cases and negative in 275 cases, indicating that the imaging findings are not necessarily diagnostic of FJA (Fig. 1).

The 28 patients in the second group who did not respond to FJI were reviewed and had severe lumbar stenosis compressing the cauda equina. Of those, 9 had decompressive laminectomy with or without fusion depending on stability of the lumbar spine with good or excellent outcomes. Four patients declined surgery and 5 patients were at high risk for requiring complex surgery and surgery was not offered to them.

DISCUSSION

The rationale for discogenic LBP is based on innervation of the outer third of the annulus fibrosis, a notion that was first suggested by Inman and Saunders in 1947 and confirmed by Malinsky in 1959 [4]. In 1981 microdissection studies showed the source of nerve fibers in the posterior

annulus fibrosis and posterior longitudinal ligament to be sinuvertebral nerves [5]. Contemporary immunofluorescence techniques later confirmed the neuropeptides within them that are typical of nociceptive axons [6].

The tears and fissures in the annulus have been seen in damaged lumbar discs and have been considered the cause of LBP [7]. Evidence that disc can hurt comes from clinical observations during operations performed with the patient under local anesthesia; probing the back of a disc was shown to reproduce pain [8,9]. Two theories have been postulated as pathogenesis of discogenic LBP.

Chemical Theory

In 1977 Marshall et al. postulated that the nucleus pulposus releases a glycoprotein that “hypothetically is a pain generator” into the nociceptors of damaged annulus and nerve roots, causing LBP and radiculitis [10]. In 2002 Saal postulated that the nucleus pulposus releases phospholipase A₂, potentially inflaming the damaged nucleus, irritating nociceptors of the annulus, and generating LBP [11].

Mechanical Theory

In 1967 Murphey hypothesized that LBP was due to stretching of the innervated annulus and posterior longitudinal ligament secondary to increase in the intradiscal pressure, the condition that is seen in bulging and herniated discs. He presented his view in this regard at the Congress of Neurological Surgeons in San Francisco [12].

The following observations provide evidence to question the legitimacy of the Murphey and the Marshall theories but not to deny the existence of discogenic LBP:

1. Bilateral discectomy with removal of the posterior annulus and posterior longitudinal ligament in patients with LBP often fails to relieve the pain, evidence that the stretched

annulus and posterior longitudinal ligament are not the source of the LBP (evidence against the mechanical and chemical theories).

2. The majority of patients who undergo microdiscectomy for free fragment disc herniation awaken from anesthesia with complete relief of radicular pain with minimal LBP despite a large hole in the annulus that allows the release of hypothetical toxic pain-generator substance from the residual disc (evidence against the Marshall theory) [1].

3. Injection of methylprednisolone and bupivacaine in the lumbar epidural space often relieves the radicular pain and confirms that the source of the radicular pain is the nerve root; however, in a prospective, randomized, double-blind study Simmons and associates demonstrated no benefit of intradiscal steroid injection in relief of LBP [13]. This finding is also evidence against Marshall's theory [10].

4. Intradiscal electrothermal therapy (IDET): The rationale for IDET is denervation of the posterior annulus by heat to relieve discogenic LBP. Advocates of the technique currently admit that the procedure is not effective in the short term but cannot explain the short-term failure. The long-term efficacy of the procedure has not been proven either (evidence against both the mechanical and chemical theories) [14-18].

5. Several intradiscal procedures have been designed by different investigators to reduce intradiscal volume and pressure, to treat CMLBP based on the mechanical theory of CMLBP [19]. None of these procedures has been effective in relieving CMLBP (evidence against the Murphey theory) [20].

- Chymopapain. In a double-blind study, Schwetschenau et al. found no benefit from chymopapain in the treatment of herniated lumbar disc [20]. However, in an open-label, double-blind study conducted in 3000 cases, the success rate was 88% for radicular pain

only. Similar results have not been achieved for CMLBP only (evidence against the Murphey theory) [21].

- Automated percutaneous lumbar discectomy (APLD). No prospective, randomized, controlled study has suggested the efficacy of APLD in CMLBP; however, such a study in patients with radicular symptoms has been reported successful (evidence against the Murphey theory) [22].
- Intradiscal laser discectomy has not proven effective in relief of LBP.
- Nucleoplasty has failed to be helpful in treatment of LBP [23-25].

6. Intradiscal injection of methylprednisolone and bupivacaine has failed to relieve the LBP [26].

In a prospective randomized study, Khot et al. concluded that the treatment is not effective in chronic LBP [27].

7. Provocative discography for the diagnosis of discogenic LBP has remained controversial for almost 50 years because the results are subjective, unreliable, and unpredictable [28-29]. This is further evidence that the innervated outer third of the annulus is not the source of the LBP. In fact, it would make sense for the test to be highly sensitive and confirmatory if the innervated annulus was the source of the CMLBP (evidence against the mechanical theory of Murphey).

8. In our series of 732 patients, 539 responded to FJI, yet 493 had pathologic discs, an incidental finding of a condition that is very common in the asymptomatic general population, arguing against discogenic LBP.

9. The rationale for arthroplasty is based on the theory of removing the pain-generating disc in CMLBP and preserving the facet joint motion [30]. The efficacy of the procedure has remained

the subject of debate among spine surgeons. As Resnick and Watter opined: “The population of patients deemed ideal for disc arthroplasty is a population who are often well treated without surgery” [31]. In 1911 Goldwaith described FJA as a cause of LBP. Twenty-two years later, in 1933, Ghormley reported FJA as a cause of LBP. The facet joints are true synovial joints with joint space, hyaline cartilage surfaces, a synovial membrane, menisci, and capsule. Two medial branches of the dorsal rami innervate the facet joints. The lower pole of each facet joint is supplied by the exiting nerve root, and the upper pole by a branch of the exiting nerve root one level higher. In facet arthropathy, a high level of prostaglandins (pain mediators) has been measured and implicated as the cause of back pain. The incidence of CMLBP secondary to FJA has been a subject of controversy [32,33]. The current literature indicates that the incidence of CMLBP due to FJA is 15% to 45% [34].

The following observations are evidence that FJA lower back pain does exist:

1. Immobilization of the facet joints by bed rest, traction, and bracing is effective in most patients with CMLBP.
2. Anti-inflammatory drugs are more effective than regular analgesics in the treatment of CMLBP because facet joints are true synovial joints in contrast to intervertebral body joints [35].
3. Lumbar facet joint denervation has been effective temporarily in patients with CMLBP who had responded to FJI.
4. Arthrodesis, with or without instrumentation, eliminates the inflamed facet joint motion without removal of the posterior annulus and posterior longitudinal ligament and has been found effective in the treatment of CMLBP in patients with severe degenerative disc disease.
5. In our experience 75.1% of the patients responded favorably to FJI in the short term. The success rate was 95% when we excluded patients who were considered red-flagged because of psychological, social, or economic factors.

Although discogenic pain due to nerve root compression causing radiculopathy and cauda equina compression due to a large disc herniation causing severe lumbar stenosis (and, as a result, LBP and neurogenic claudication) are not debatable, we question the legitimacy of LBP based on the Marshall and the Murphey theories.

Our success rate in FJI is higher than what has been reported previously in the literature (15%–45%) [34]. Discussion regarding denervation of facet joints and the surgical treatment of MLBP including laminectomy and arthrodesis is beyond the scope of this article [1,2].

CONCLUSION

This study was retrospective and noncontrolled and therefore does not prove that discogenic LBP does not exist; however, it questions the legitimacy of the Murphey and the Marshall theories in pathogenesis of LBP. Our study suggests that it is reasonable in patients with CMLBP for treating physicians to first address the abnormal facet joints rather than the pathologic discs seen on MRI. Our experience suggests that the FJI is often a palliative rather than a curative treatment.

Acknowledgments: The authors wish to thank Navid Tabibzadeh, a Doctor of Osteopathy candidate, for assistance in compiling illustrations for this article.

Competing interests: N/A

Funding: None

REFERENCES

1. Sybert GW, Joy Arpin-Sybert E. Evaluation and management of the failed back syndrome. In Youmans neurological surgery, edn 5, vol 4. Edited by Winn HR, Youmans JR. Philadelphia: WB Saunders; 2003; 4327-4345.
2. Rensick DK, Choudhri TF, Dailey AT, Groff MW, Khoo L, Matz PG, Mummaneni P, Watters WC 3rd, Wang J, Walters BC, Hadley MN; American Association of Neurological Surgeons/Congress of Neurological Surgeons. Guidelines for the performance of fusion procedures for degenerative disease of the lumbar spine. Part 8: lumbar fusion for disc herniation and radiculopathy. *J Neurosurg Spine* 2005;2:673-678.
3. Merskey H. Classification of chronic pain: description of chronic pain syndromes and definition of pain terms. *Pain Suppl* 1986;3:S1(3).
4. Inman VT, Saunders JB de CM. Anatomicophysiological aspects of injuries to the intervertebral disc. *J Bone Joint Surg Am* 1947;29:461-534.
5. Bogduk N, Tynan W, Wilson AS. The nerve supply to human lumbar intervertebral discs. *J Anat* 1981;132:39-56.
6. Konttinen YT, Gronbald M, Antti-Poika I. Neuroimmunohistochemical analysis of peridiscal nociceptive neural elements. *Spine* 1990;15:383-386.
7. Peng B, Wu W, Hou S, Li P, Zhang C, Yang Y. The pathogenesis of discogenic low back pain. *J Bone Joint Surg Br* 2005;87:1.
8. Falconer MA, McGeorge M, Begg AC. Observations on the cause and mechanism of symptom-production in sciatica and low-back pain. *J Neurol Neurosurg Psychiatry* 1948;11:13-26.
9. Wiberg G. Back pain in relation to the nerve supply of the intervertebral disc. *Acta Orthop Scand* 1949;19:211-221.
10. Marshall LL, Trethewie ER, Curtain CC. Chemical radiculitis. A clinical, physiological and immunological study. *Clin Orthop* 1977;129:61-7.
11. Saal JS. General principles of diagnostic testing as related to painful lumbar spine disorders: a critical appraisal of current diagnostic techniques. *Spine* 2002;27:22, 2538-2545; discussion

2546.

12. Murphy F. Sources and patterns of pain in disc disease. *Clin Neurosurg* 1968;15:343-351.
13. Simmons JW, McMillin JN, Emery SF, Kimmich SJ. Intradiscal steroids. A prospective double-blind clinical trial. *Spine* 1992;17(6 Suppl):S172-S175.
14. Biyani A, Andersson GB, Chaudhary H, An HS. Intradiscal electrothermal therapy: A treatment option in patients with internal disc disruption. *Spine* 2003;28(15 Suppl):S8-14.
15. Cohen SP, Williams S, Kurihara C, Griffith S, Larkin TM. Nucleoplasty with or without intradiscal electrothermal therapy (IDET) as a treatment for lumbar herniated disc. *J Spinal Disord Tech* 2005;18(Suppl):S119-S124.
16. Davis TT, Delamarter RB, Sra P, Goldstein TB. The IDET procedure for chronic discogenic low back pain. *Spine* 2004;29:752-756.
17. Saal JA, Saal JS. Intradiscal electrothermal treatment for chronic discogenic low back pain: prospective outcome study with a minimal 2-year follow-up. *Spine* 2002;27:966-973; discussion 973-974.
18. Freeman B, Fraser RD, Cain CM, Hall DJ, Chapple DC. A randomized, double-blind, controlled trial: intradiscal electrothermal therapy versus placebo for the treatment of chronic discogenic low back pain; *Spine* 2005;30:2369-2377; discussion 2378.
19. Andreula C, Muto M, Leonardi M. Interventional spinal procedures. *Eur J Radiol* 2004;50:112-119.
20. Schwetschenau PR, Ramirez A, Johnston J, Wiggs C, Martins A. Double-blind evaluation of intradiscal chymopapain for herniated lumbar discs: early results. *J Neurosurg* 1976;45:622-627.
21. Kim YS, Chin DK, Yoon DH, Jin BH, Cho YE. Predictors of successful outcome for lumbar chemonucleolysis: analysis of 3000 cases during the past 14 years. *Neurosurgery* 2002;51(5 Suppl):S123-S128.
22. Onik GM, Helms C. Nuances in percutaneous discectomy. *Radiol Clin North Am* 1998;36:523-532.
23. Erdine S, Ozyalcin SN, Cimen A. Perkutan lomber nukleoplasti [in Turkish]. *Agri* 2005;17:2.
24. Marin FZ. CAM versus nucleoplasty. *Acta Neurochir* 2005;Suppl 92:111-114.

25. Welch WC, Gerszten PC. Alternative strategies for lumbar discectomy: intradiscal electrothermy and nucleoplasty. *Neurosurg Focus* 2002;13:E7.
26. Buttermann GR. The effect of spinal steroid injections for degenerative disc disease. *Spine J* 2004;4:495-505.
27. Khot A, Bowditch M, Powell J, Sharp D. The use of intradiscal steroid therapy for lumbar spinal discogenic pain: a randomized controlled trial. *Spine* 2004;29:833-836; discussion 837.
28. Bogduk N. Diskography. *APS Journal* 1994;3:149-154.
29. Guyer RD, Ohnmeiss DD. Lumbar discography. *Spine J* 2003;3(3 Suppl):11S-27S.
30. Blumenthal S, McAfee PC, Guyer RD, Hochschuler SH, Geisler FH, Holt RT, Garcia R Jr, Regan JJ, Ohnmeiss DD. A prospective, randomized, multicenter Food and Drug Administration investigational device exemptions study of lumbar total disc replacement with the CHARITE Artificial disc versus lumbar fusion. *Spine* 2005;30(14 Suppl):1565-1575.
31. Resnick DK, Watters WC. Lumbar disc arthroplasty: A critical review. *Clin Neurosurg* 2007;54:83-87.
32. Jackson RP, Jacobs RR, Montesano PX. 1988 Volvo award in clinical sciences. Facet joint injection in low-back pain. A prospective statistical study. *Spine* 1988;13:(966-971).
33. Schwarzer AC, Aprill CN, Derby R, Fortin J, Kine G, Bogduc N. Clinical features of patients with pain stemming from the lumbar zygapophysial joints: Is the lumbar facet syndrome a clinical entity? *Spine* 1994;19:1132-1137.
34. Manchikanti L, Boswell MV, Singh V, Pampati V, Darmon KS, Beyer CD. Prevalence of facet joint pain in chronic spinal pain of cervical, thoracic and lumbar regions. *BMC Musculoskeletal Disorders* 2004;5:15.
35. Shin CH. Lumbar facet arthropathy: history of facet joint arthropathy, pathophysiology of pain secondary to facet joint arthropathy, NSAID drug of choice. 2005, pp 1-20 (<http://www.emedicine.com/pmr/topic 68.html>).

Fig. 1. MRI findings in the lumbar spine. Some patients had multiple findings. (A) In 732 cases.
(B) In percentage of 732 cases.

Table 1. Patient demographics

Total patients, <i>n</i>	732
Mean age, <i>y</i>	51
Age range, <i>y</i>	19–89
Sex	
Male, <i>n</i> (%)	256 (35)
Female, <i>n</i> (%)	256 (35)
Period of data collection	1997–2007
Duration of preexisting back pain (range)	3 mo–43 y
Duration of pain-free interval after FJI till pain recurrence, <i>y</i> (range)	0–5

FJI, facet joint injection.

Table 2. FJI outcomes according to Odom's criteria

Odom's classification	<i>n</i> (%)
I (excellent)	182 (25)
II (good)	367 (50.1)

III (fair)	128 (17.5)
IV (poor)	55 (7.4)
I+II (success rate)	549 (75.1)

Odom's criteria:

Excellent: all preoperative symptoms relieved, abnormal finding improved.

Good: minimal persistence of preoperative symptoms, abnormal finding unchanged or improved.

Fair: definite relief of some preoperative symptoms, others unchanged or slightly improved.

Poor: symptoms and signs unchanged or exacerbated.

FJI, facet joint injection.

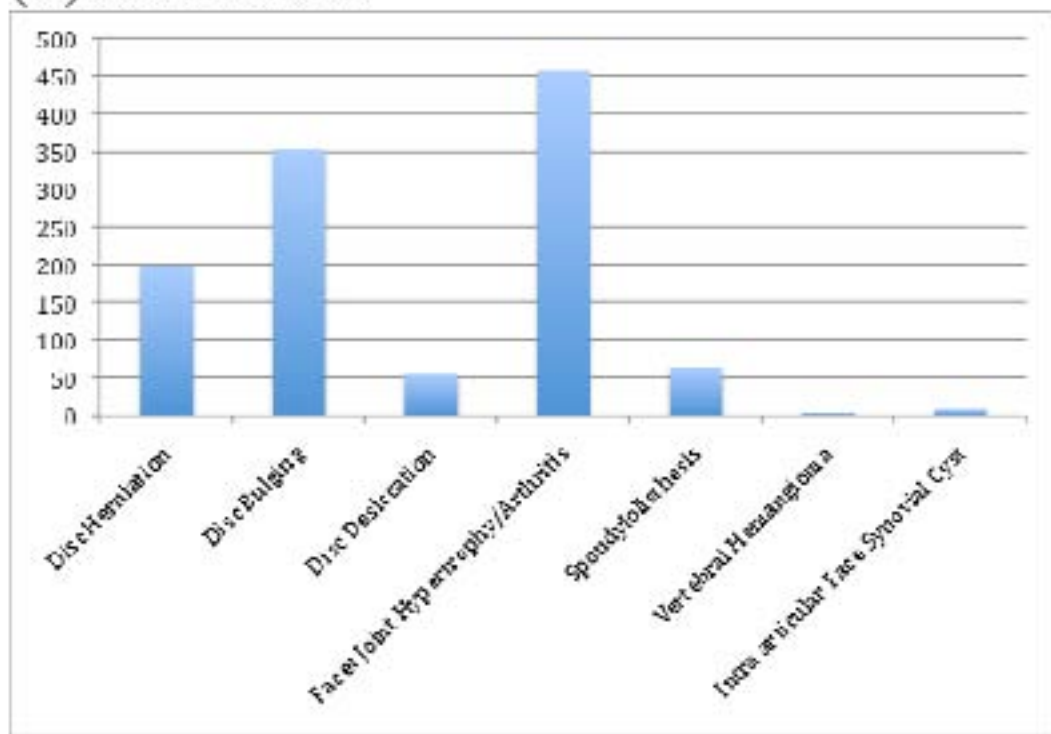
Table 3. Comparison of success and failure rates following FJI before and after exclusion of possible psychological, social, and economic reasons for failure

Outcome	Before	After
Success rate, %	73.2	86.8
Failure rate, %	24.9	5
Treatment efficacy, <i>d</i>	77.9	88.6

FJI, facet joint injection.

Graph 1 (A&B): MRI Findings of Lumbar Spine. Some patients had multiple findings.

(A) In 732 cases.



(B) In percentage of 732 cases.

